

REPLANTATION OF AVULSED TEETH

MUTHU MS

GOOD AFTERNOON

Welcome
All particpants

OVERVIEW

- Fundamentals and IADT Guidelines
- Assessment and Trauma Phone Call
- Protocols for Permanent Teeth
- Primary Teeth ? Evidence?
- Exam Questions
- Recap
- Conclusion

Section 1 - Fundamentals and guidelines

1.a. Fundamentals of Avulsion
1.b. IADT Guidelines

1.a. Fundamentals of Avulsion

What is Avulsion?

Total Displacement of the Tooth out of its Socket

Two Important Determinants

Extra Oral Dry Time
Transport Medium

Ultimate Goal in Management

Reattachment of Periodontal Ligament to the Alveolar Bone

Survival of the Fibroblasts of PDL

1.b. IADT Guidelines

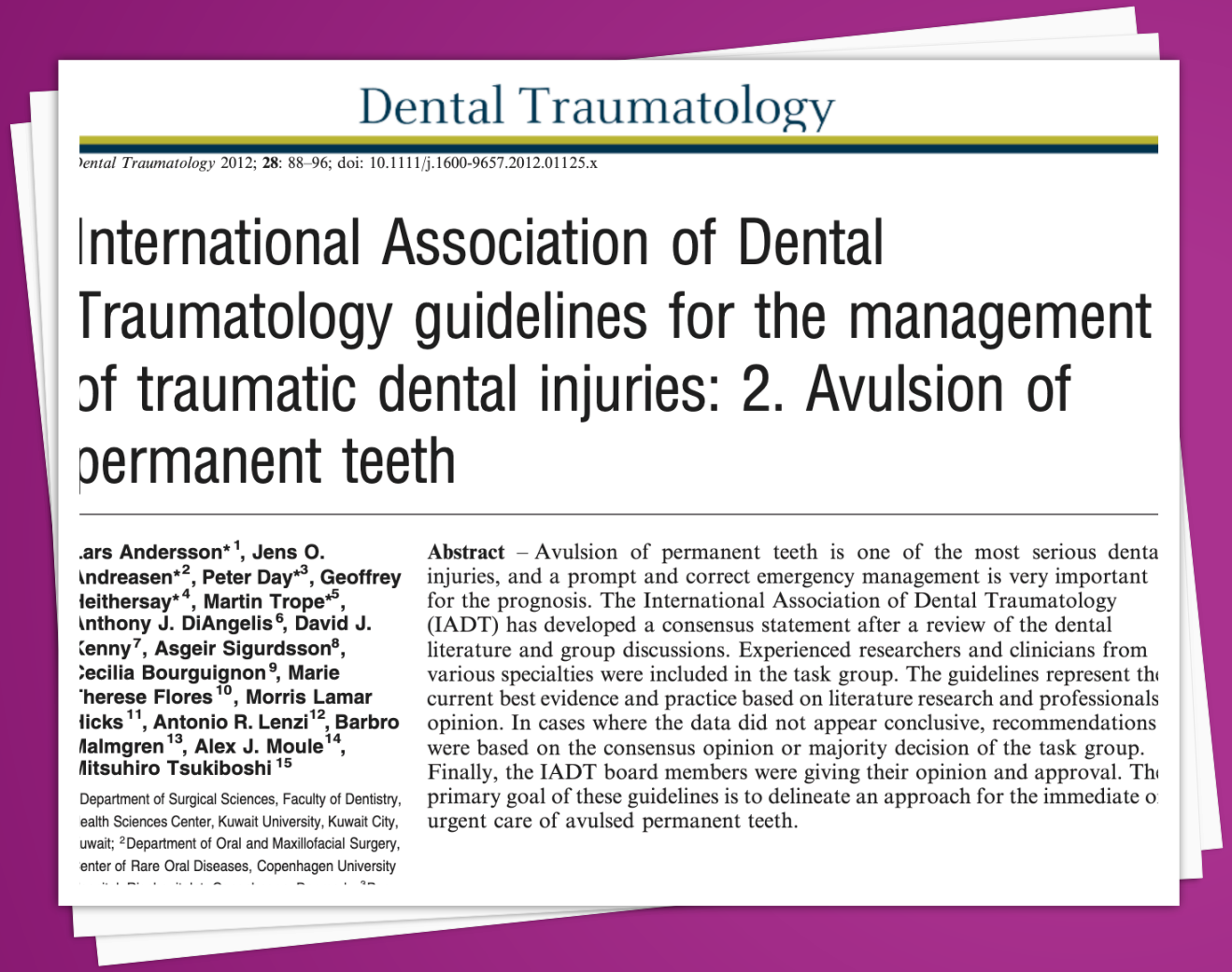

Dental Traumatology

ental Traumatology 2012; **28**: 88–96; doi: 10.1111/j.1600-9657.2012.01125.x

International Association of Dental Traumatology guidelines for the management of traumatic dental injuries: 2. Avulsion of permanent teeth

ars Andersson*[1], Jens O. ndreasen*[2], Peter Day*[3], Geoffrey leithersay*[4], Martin Trope*[5], nthony J. DiAngelis[6], David J. enny[7], Asgeir Sigurdsson[8], ecilia Bourguignon[9], Marie herese Flores[10], Morris Lamar icks[11], Antonio R. Lenzi[12], Barbro almgren[13], Alex J. Moule[14], itsuhiro Tsukiboshi[15]

Department of Surgical Sciences, Faculty of Dentistry, ealth Sciences Center, Kuwait University, Kuwait City, uwait; [2]Department of Oral and Maxillofacial Surgery, enter of Rare Oral Diseases, Copenhagen University

Abstract – Avulsion of permanent teeth is one of the most serious denta injuries, and a prompt and correct emergency management is very important for the prognosis. The International Association of Dental Traumatology (IADT) has developed a consensus statement after a review of the dental literature and group discussions. Experienced researchers and clinicians from various specialties were included in the task group. The guidelines represent th current best evidence and practice based on literature research and professionals opinion. In cases where the data did not appear conclusive, recommendations were based on the consensus opinion or majority decision of the task group. Finally, the IADT board members were giving their opinion and approval. Th primary goal of these guidelines is to delineate an approach for the immediate o urgent care of avulsed permanent teeth.

INTERNATIONAL ASSOCIATION OF DENTAL TRAUMATOLOGY GUIDELINES

2012

Section 2 - Trauma Phone Call and Assessment

2.a. Trauma Phone Call
2.b. Assessment of the Avulsed Tooth

2.a. Trauma Phone Call

Trauma Phone Call

1. Age of the Patient
2. Guide Them/Others To Replant the Tooth Into the Socket

At the Site of Accident (To Perform or Instruct)

- Keep the patient calm (patient consciousness)
- Ensure avulsion of tooth
- Pick the tooth by crown
- Avoid touching the root
- Wash it briefly (10secs) using cold running water
- Try to encourage patient/ guardian to replant the tooth
- Bite on a handkerchief to hold in position
- If could not replant and If HBSS or Viaspan is available or Milk, Saline - Transport the tooth and meet the dentist

When Not To Replant?

- Periodontal disease
- Severe Caries
- Uncooperative patient
- Medical condition (Immunosuppression, Cardiac conditions)

2.b. Assessment of the Avulsed Tooth

Replantation Protocol - Basic Assessment

- Maturity of the root - **Open apex or closed apex**

- **Condition of the pdl cells** - Depends on the storage medium and the time out of the mouth (especially dry time)



Replantation Protocol - Three Categories

- The pdl cells are most likely **VIABLE**
- The pdl cells **MAY BE VIABLE but COMPROMISED**
- The pdl cells are **NOT VIABLE**



Replantation Protocol - Three Categories

- The tooth has been replanted before the patients arrival at the clinic - **pdl cells viable**
- The tooth has been kept in a physiologic storage medium or osmolality balanced medium and/or stored dry, the extra oral dry time has been less than 60 mins - **pdl cells may be viable**
- Dry time longer than 60 mins or other reasons suggesting **non-viable cells**



Section 3 - Protocols for Permanent Teeth

3.a. Protocols - Closed Apex
3.b. Protocols - Open Apex

3.a.Protocols for Avulsed Permanent Teeth - Closed Apex

Avulsed Teeth - Closed Apex - Protocols - Three Possibilities

- The tooth has been replanted before the patients arrival at the clinic - **pdl cells viable**
- The tooth has been kept in a physiologic storage medium or osmolality balanced medium and/ or stored dry, the extra oral dry time has been less than 60 mins - **pdl cells may be viable**
- Dry time longer than 60 mins or other reasons suggesting **non-viable cells**

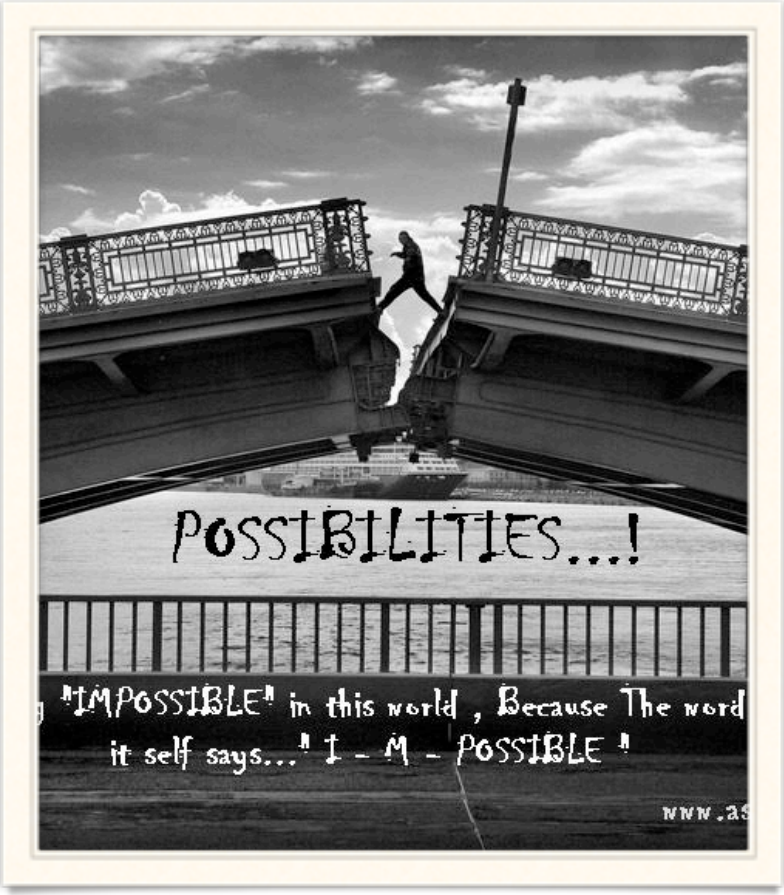

1a) Viable Cells - Closed Apex

- **Leave the tooth in place.**
- Clean the area with water spray, saline, or chlorhexidine.
- Suture gingival lacerations, if present.
- Verify normal position of the replanted tooth both clinically and radiographically.

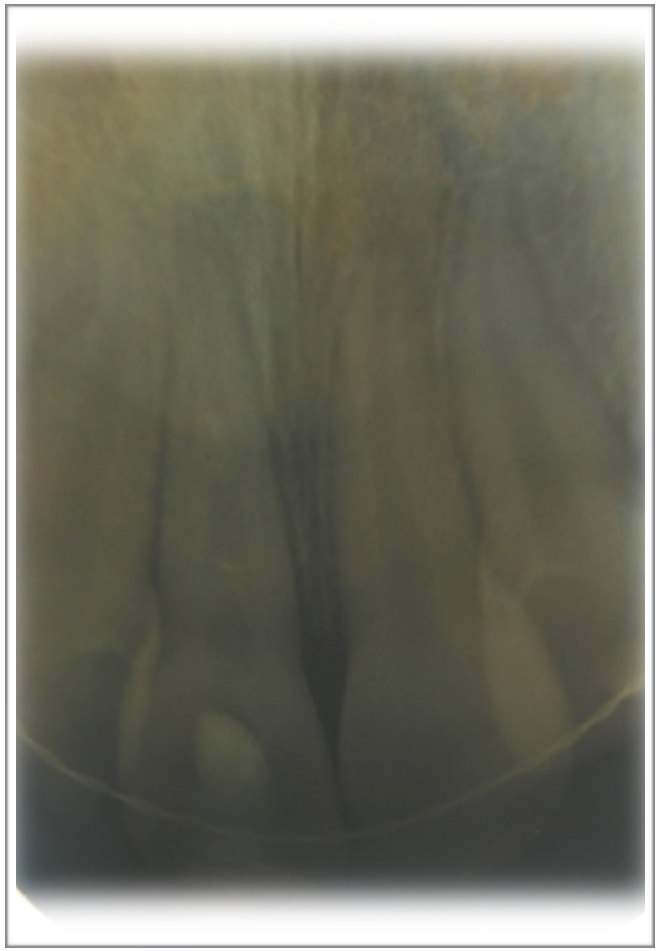

1a) Viable Cells - Closed Apex

- Apply a flexible splint for up to 2 weeks.
- Administer systemic antibiotics
- Check tetanus protection.
- Give patient instructions.
- Initiate root canal treatment 7–10 days after replantation and before splint removal.

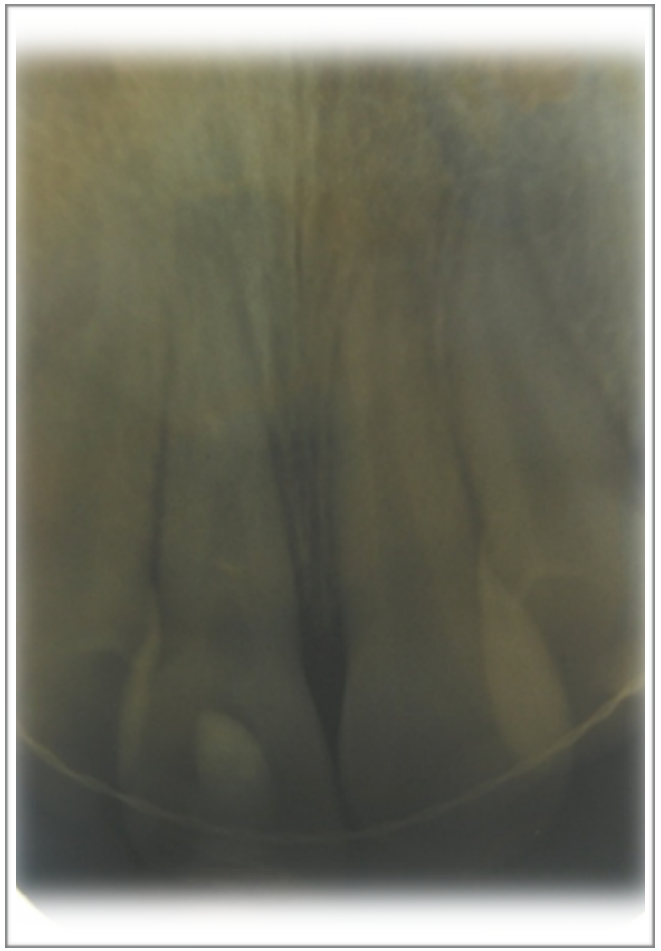

1B) May Be Viable Cells - Closed Apex

- Clean the **root surface and apical foramen with a stream of saline and soak the tooth in saline** thereby removing contamination and dead cells from the root surface.
- Administer local anesthesia.
- Irrigate the socket with saline.
- Examine the alveolar socket. If there is a fracture of the socket wall, reposition it with a suitable instrument.

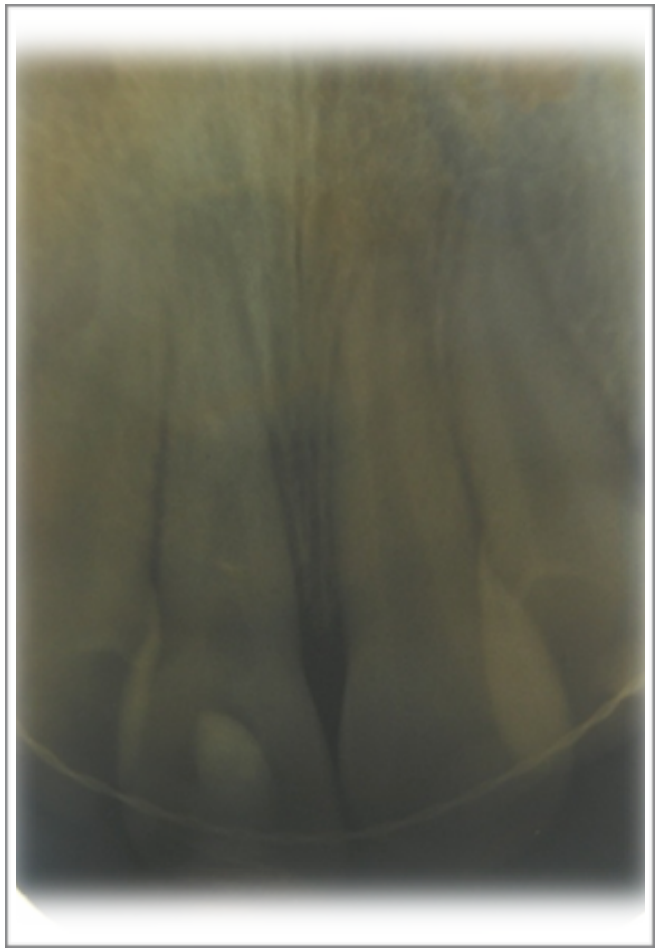

1B) May Be Viable Cells - Closed Apex

- Replant the tooth slowly with slight digital pressure. Do not use force.
- Suture gingival lacerations, if present.
- Verify normal position of the replanted tooth both clinically and radiographically.
- Apply a flexible splint for up to 2 weeks, keep away from the gingiva.

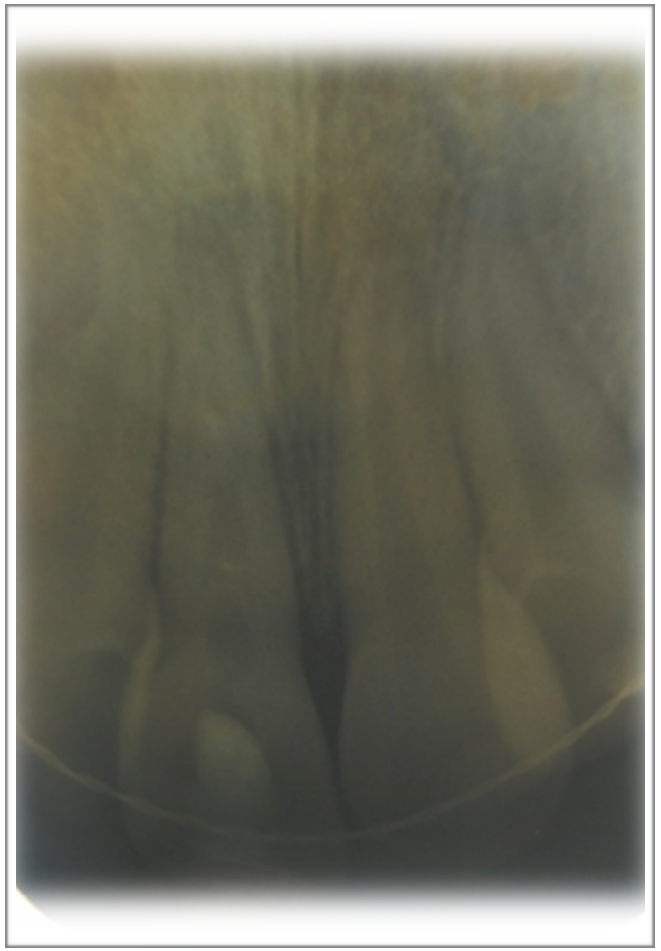

1B) May Be Viable Cells - Closed Apex

- Administer systemic antibiotics.
- Check tetanus protection.
- Give patient instructions.
- Initiate root canal treatment 7–10 days after replantation and before splint removal.

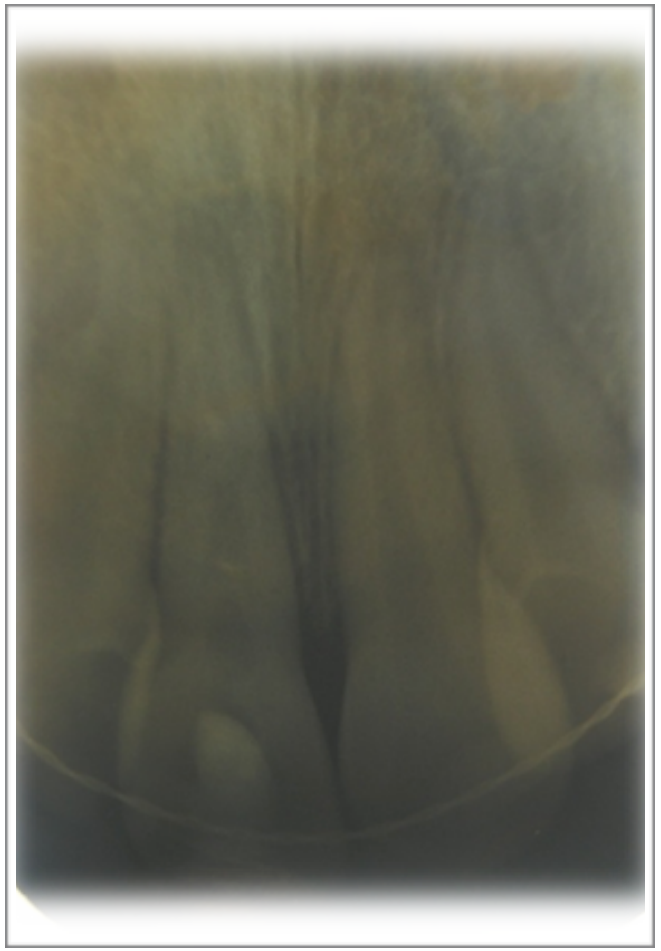

1C) Not Viable Cells - Closed Apex

- **Remove attached non-viable soft tissue carefully, for example, with gauze.** The best way to this has not yet been decided.
- Root canal treatment to the tooth can be carried out prior to replantation or later.
- In cases of delayed replantation, root canal treatment should be either carried out on the tooth prior to replantation or it can be carried out 7–10 days later like in other replantation situations.

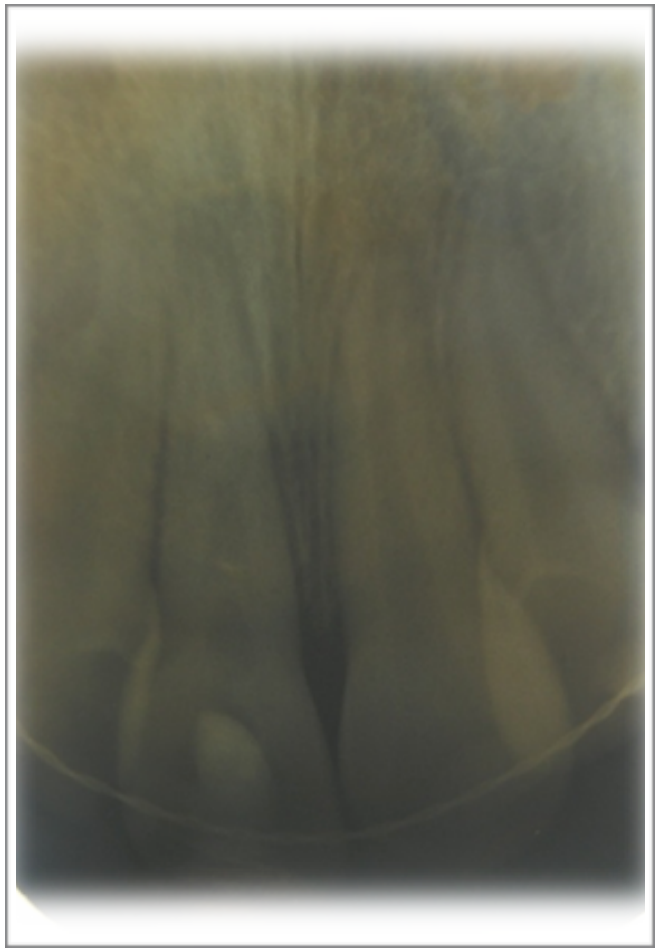

1C) Not Viable Cells - Closed Apex

- Administer local anesthesia.
- Irrigate the socket with saline.
- Examine the alveolar socket. If there is a fracture of the socket wall, reposition it with a suitable instrument.
- Replant the tooth.

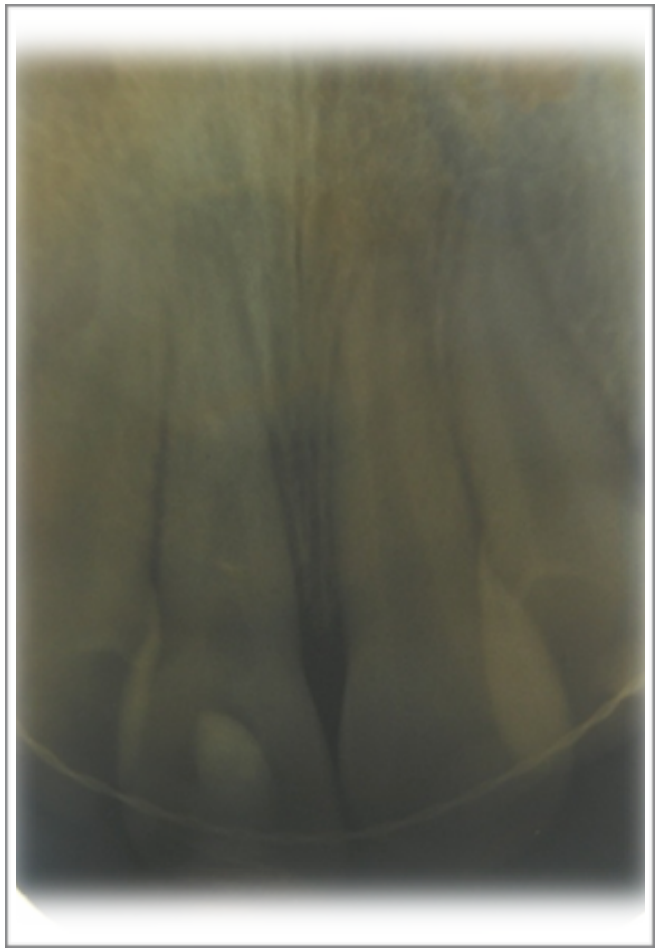

1C) Not Viable Cells - Closed Apex

- Suture gingival lacerations, if present.
- Verify normal position of the replanted tooth clinically and radiographically.
- Stabilize the tooth for **4 weeks** using a flexible splint.
- Administration of systemic antibiotics.
- Check tetanus protection.

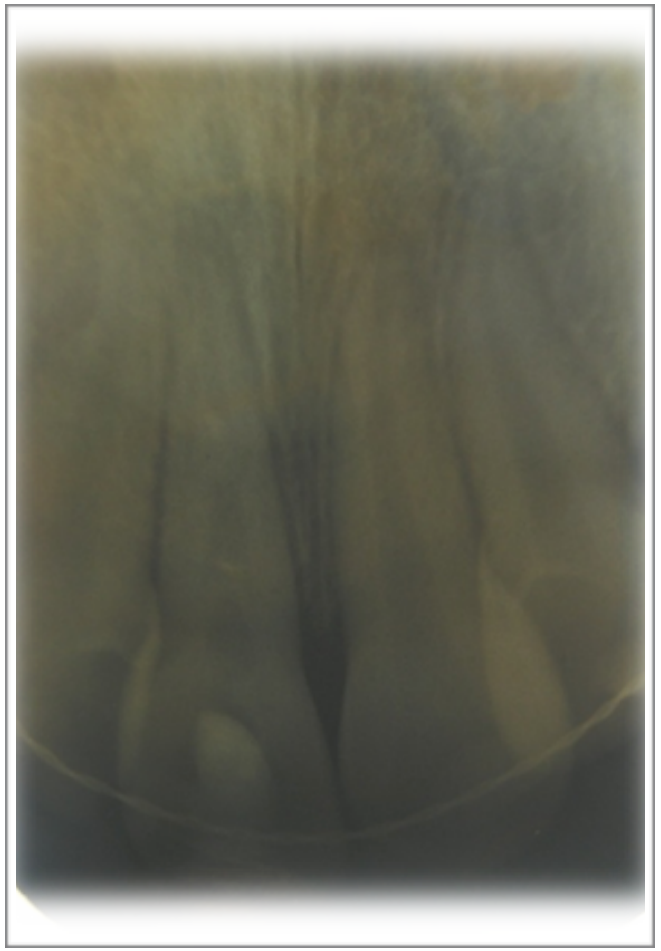

1C) Not Viable Cells - Closed Apex

- Give patient instructions.
- To **slow down osseous replacement of the tooth,** treatment of the root surface with fluoride prior to replantation has been suggested **(2% sodium fluoride solution for 20 min)** but it should not be seen as an absolute recommendation.

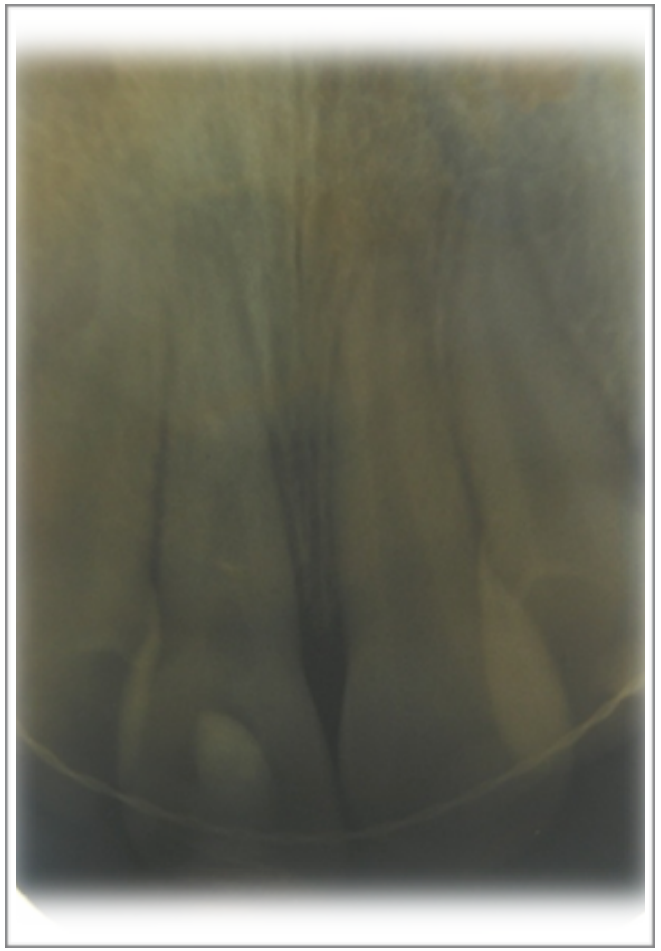

3.b.Protocols for Avulsed Permanent Teeth - Open Apex

Avulsed Teeth - Open Apex - Protocols
3 Possibilities

- The tooth has been replanted before the patients arrival at the clinic - **pdl cells viable**
- The tooth has been kept in a physiologic storage medium or osmolality balanced medium and/ or stored dry, the extra oral dry time has been less than 60 mins - **pdl cells may be viable**
- Dry time longer than 60 mins or other reasons suggesting **non-viable cells**

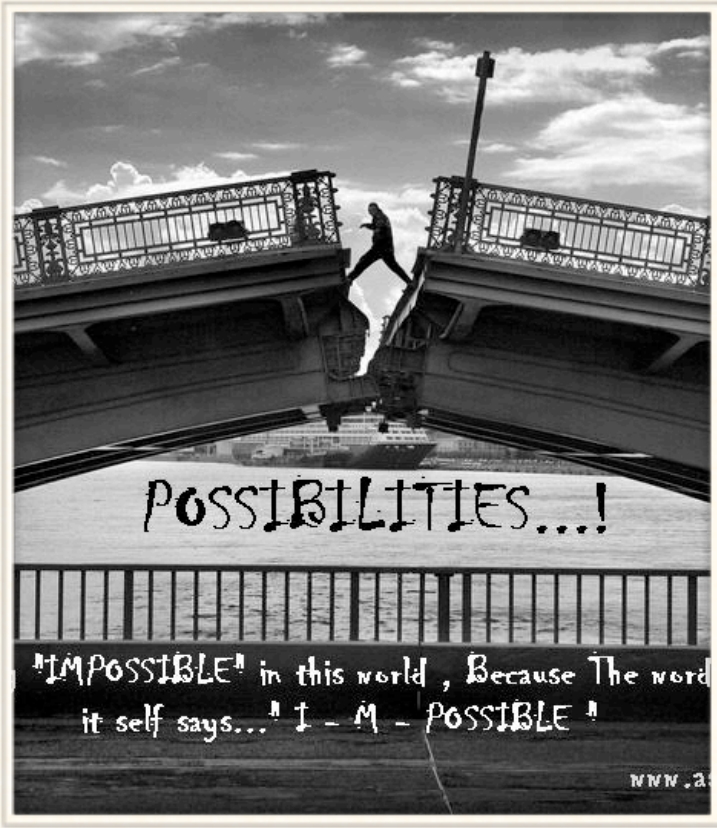

1a) Viable Cells - Open Apex

- **Leave the tooth in place.**
- Clean the area with water spray, saline, or chlorhexidine
- Suture gingival lacerations, if present.
- Verify normal position of the replanted tooth both clinically and radiographically

1a) Viable Cells - Open Apex

- Apply a flexible splint for up to 2 weeks.
- Administer systemic antibiotics.
- Check tetanus protection.
- Give patient instructions

1a) Viable Cells - Open Apex

- The **goal** for replanting still-developing (immature) teeth in children is to **allow for possible revascularization** of the pulp space. If that does not occur, rootcanal treatment may be recommended.

1b) May Be Viable Cells - Open Apex

- **If contaminated, clean the root surface and apical foramen with a stream of saline.**
- Topical application of antibiotics has been shown to enhance chances for revascularization of the pulp and can be considered if available.
- Administer local anesthesia.
- Examine the alveolar socket. If there is a fracture of the socket wall, reposition it with a suitable instrument.

1b) May Be Viable Cells - Open Apex

- Remove the coagulum in the socket and replant the tooth slowly with slight digital pressure.
- Suture gingival lacerations, especially in the cervical area.
- Verify normal position of the replanted tooth clinically and radiographically.
- Apply a flexible splint for up to 2 weeks.
- Administer systemic antibiotics.

1b) May Be Viable Cells - Open Apex

- Check tetanus protection.
- Give patient instructions.
- The **goal** for replanting still-developing (immature) teeth in children is to **allow for possible revascularization** of the pulp space. The risk of infection-related root resorption should be weighed up against the chances of revascularization. Such resorption is very rapid in teeth of children. If revascularization does not occur, root canal treatment may be recommended.

1c) Not Viable Cells - Open Apex

- **Remove attached non-viable soft tissue carefully, for example, with gauze.** The best way to this has not yet been decided.
- Root canal treatment to the tooth can be carried out prior to replantation or later.
- Administer local anesthesia.
- Remove the coagulum from the socket with a stream of saline. Examine the alveolar socket. If there is a fracture of the socket wall, reposition it with a suitable instrument.

1c) Not Viable Cells - Open Apex

- Replant the tooth slowly with slight digital pressure.
- Suture gingival laceration.
- Verify normal position of the replanted tooth clinically and radiographically.
- **Stabilize the tooth for 4 weeks** using a flexible splint.
- Administer systemic antibiotics.
- Check tetanus protection.

1c) Not Viable Cells - Open Apex

- Give patient instructions.
- The **goal** is to **slow down osseous replacement of the tooth,** treatment of the **root surface with fluoride prior to replantation (2% sodium fluoride solution for 20 min)** has been suggested but it should not be seen as an absolute recommendation.

Other Important Aspects

- LA with adrenaline can be used. Evidence against this is weak.
- If necessary tetanus booster dose
- Short term flexibile splints
- Splinting upto 2 weeks
- 4 weeks, 3 months, 6 months, 12 months - xray
- Thereafter every year

When To Do RCT?

- Ideal time is within 7-10 days after replantation
- If dry time more than 60 mins - RCT can be done prior to replantation
- CaOH dressing for a month
- For open apex - Wait until signs of necrosis

Do We Need Systemic Antibiotics?

- Tetracycline is the first choice
- Amoxycillin can be given
- Surface treatment of the tooth - Minocycline or doxycycline - 1 mg per 20 ml of saline for 5 min soak

Patient Instructions

- No Contact sports
- Soft diet for 2 weeks
- Brush teeth with soft brush after **<u>every meal</u>**
- Use chlorhexidine mouthrinse (0.1%) twice a day for a week

Section 4 - Replantation of Primary Teeth

Should We Consider?

PRIMARY TEETH

Replantation

Dental Traumatology

Dental Traumatology 2012; **28**: 174–182; doi: 10.1111/j.1600-9657.2012.01146.x

International Association of Dental Traumatology guidelines for the management of traumatic dental injuries: 3. Injuries in the primary dentition

Barbro Malmgren[1,*], Jens O. Andreasen[2,*], Marie Therese Flores[3,*], Agneta Robertson[4,*], Anthony J. DiAngelis[5,*], Lars Andersson[6], Giacomo Cavalleri[7], Nestor Cohenca[8], Peter Day[9], Morris Lamar Hicks[10], Olle Malmgren[11], Alex J. Moule[12], Juan Onetto[13], Mitsuhiro Tsukiboshi[14]

[1]Division of Pediatric Dentistry, Department of Dental Medicine, Karolinska Institutet, Huddinge, Sweden; [2]Department of Oral and Maxillofacial Surgery, Center of Rare Oral Diseases, Copenhagen University Hospital, Rigshospitalet, Copenhagen, Denmark; [3]Department of Pediatric Dentistry, Faculty of Dentistry, Universidad de Valparaiso, Valparaiso, Chile; [4]Department of Pedodontics,

Abstract – Traumatic injuries to the primary dentition present special problems and the management is often different as compared with the permanent dentition. The International Association of Dental Traumatology (IADT) has developed a consensus statement after a review of the dental literature and group discussions. Experienced researchers and clinicians from various specialities were included in the task group. In cases where the data did not appear conclusive, recommendations were based on the consensus opinion or majority decision of the task group. Finally, the IADT board members were giving their opinion and approval. The primary goal of these guidelines is to delineate an approach for the immediate or urgent care for management of primary teeth injuries. The IADT cannot and does not guarantee favorable outcomes from strict adherence to the guidelines, but believe that their application can maximize the chances of a positive outcome.

Malmgren B et al . International association of dental traumatology guidelines for the management of traumatic dental injuries: 3. Injuries in the primary dentition. Dent Traumatol 2012; 28: 174-182.

This guideline does not recommend the replantation of primary teeth

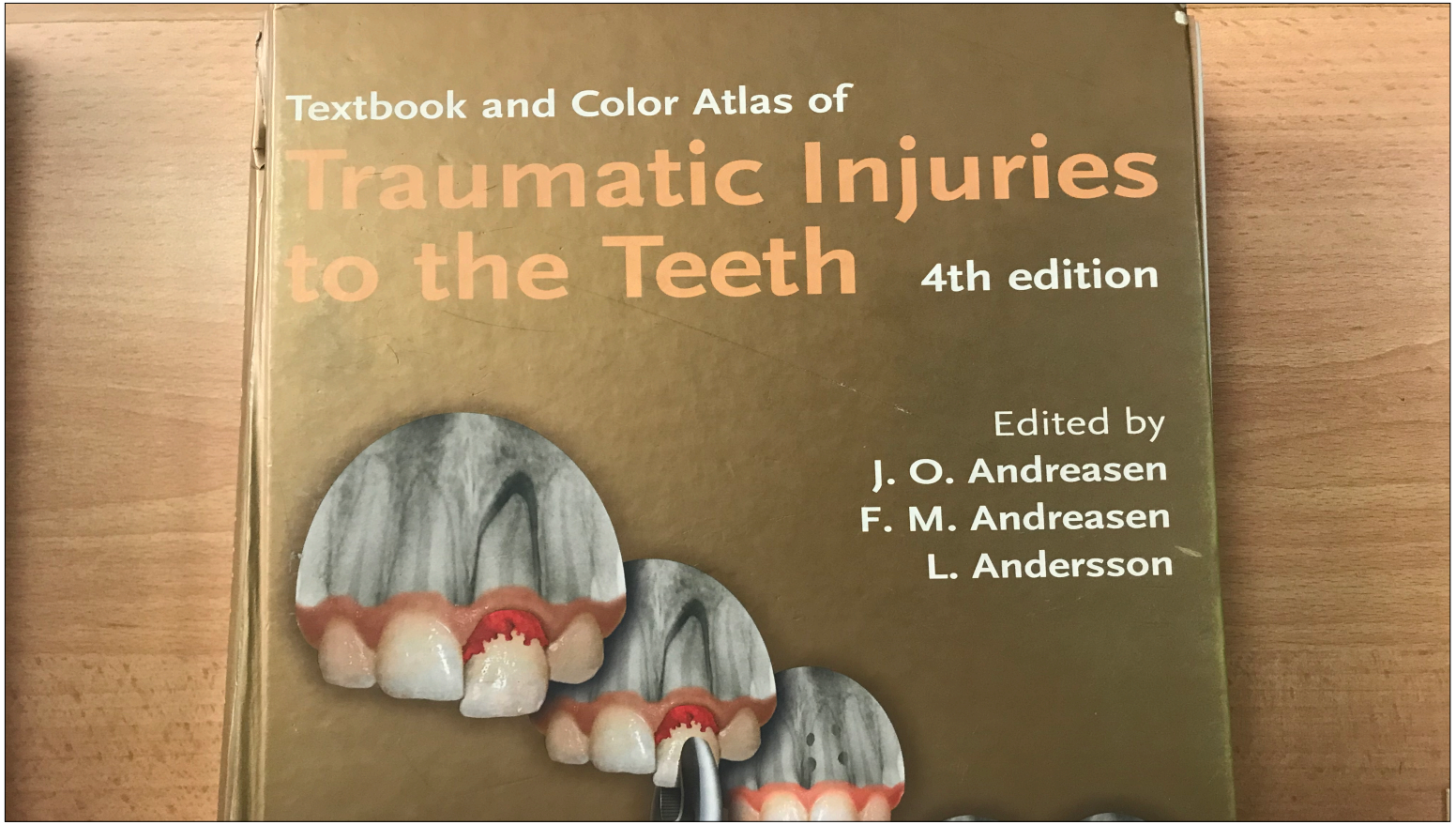

Andreasen JO, Andreasen FM, Andersson L. Textbook and color atlas of Traumatic Injuries to the teeth. 4th edition, Blackwell Munksgaard, Copenhagen, Denmark, **2016**, p 530.

This practice **cannot be recommended until further evidence** suggests that the permanent successor will not be involved, because **replantation of a primary tooth may displace a coagulum into the follicle of the permanent incisor**. Periapical inflammation subsequent to pulp necrosis may cause mineralization disturbances in the permanent dentition.

Replantation of avulsed primary teeth: a systematic review

PAULO ANTÔNIO MARTINS-JÚNIOR[1], FELIPE AUGUSTO DA SILVA FRANCO[1], RAMON VALERIO DE BARCELOS[1], LEANDRO SILVA MARQUES[2] & MARIA LETÍCIA RAMOS-JORGE[1]

[1]Department of Pediatric Dentistry, Federal University of Vales do Jequitinhonha e Mucuri, Diamantina, Brazil, and
[2]Department of Orthodontics, Federal University of Vales do Jequitinhonha e Mucuri, Diamantina, Brazil

International Journal of Paediatric Dentistry 2014; 24: 77–83

Background. There is little evidence regarding the risks and benefits of replantation of avulsed primary teeth.
Aim. The aim of this study was to perform a systematic review of the literature on the replantation of avulsed primary teeth, analysing the risks and benefits to help guide dentists regarding the best clinical decision-making in such cases.
Design. The Medline/Pubmed, LILACS, and SciELO databases were searched for articles published in English, Portuguese, German or Spanish on the replantation of avulsed primary teeth in dental journals dating from the inception of the databases through to May 2013.
Results. Among the 891 papers identified in the search, nineteen fulfilled the inclusion criteria. All 19 studies were case reports involving a total of 41 replanted primary teeth. No negative consequences to either the primary tooth or permanent successor were observed in 15 cases. Among the other 26 cases, there were negative consequences to only the replanted primary tooth in 16 cases, only the permanent successor in three cases and both the replanted primary tooth and permanent successor in seven cases.
Conclusion. There is a lack of high-quality studies that can help guide clinicians regarding the best approach in cases of primary tooth avulsion.

Martins-Junior PA et al. Replantation of avulsed primary teeth : a systematic review. Int J Ped Dent 2014; 24: 77-83.

Dental Traumatology

Dental Traumatology 2013; **29**: 178–184; doi: 10.1111/edt.12038

Replantation of avulsed primary incisors: a critical review of a controversial treatment

Gideon Holan

Department of Pediatric Dentistry, The Hebrew University – Hadassah School of Dental Medicine, Jerusalem, Israel

Key words: avulsion; replantation; primary teeth; review

Correspondence to: Gideon Holan, Department of Pediatric Dentistry, Hadassah School of Dental Medicine, PO 12272, Jerusalem 91120, Israel
Tel.: 972 2 6776124
Fax: 972 2 6431747
e-mail: holan@cc.huji.ac.il

Accepted 16 January, 2013

Abstract – Compared with the abundant literature on the replantation of avulsed permanent teeth, the literature on replantation of avulsed primary teeth is significantly more limited. A search of PubMed, using the terms: primary teeth, primary incisors, avulsion, exarticulation, replantation and reposition, and search in the reference list of the relevant articles, revealed 16 case reports of replantation of 31 primary incisors in 24 children. This article is a critical review of the arguments against replantation that have been presented in textbooks, review articles, and clinical guidelines.

Holan G. Replantation of avulsed primary incisors : a critical review of a controversial treatment. **Dent Traumatol 2013**; 29: 178-184.

This review indicates that, in the absence of high-quality evidence, replantation should not be **formally** recommended

One of the major objections to replant an avulsed primary tooth is.....

Injury to the developing permanent successor

Smelhaus S (1925), Kokich VG et al (1985), Filippi et al (1997)

Moral of the story

Presently, replantation of avulsed primary incisors is not "evidence-based care' and therefore cannot be **formally** recommended. However, a general attitude of **"look for the evidence"** should be adopted, rather than negation based on anecdotal evidence from statements made in published works.

Holan G. Replantation of avulsed primary incisors : a critical review of a controversial treatment. **Dent Traumatol 2013;** 29: 178-184.

Section 5 - Exams and Questions

Questions in the Exams

EXAM QUESTIONS

- Give brief account of extra-alveolar time and replantation of teeth
- Therapeutic protocol for an avulsed permanent tooth
- Discuss the current guidelines on the management of traumatic injuries to the primary dentition.
- Classify injuries to anterior teeth. Write in detail about avulsion in primary and permanent dentition.
- Discuss in detail the clinical management of avulsed primary and permanent anterior teeth. Elaborate on recent concepts on storage media, extra-oral time and other parameters in the long term success of such teeth; supporting your answer with literature

EXAM QUESTIONS

- Therapeutic protocol for avulsed teeth
- Explain in detail about the various storage media available for avulsed tooth and its clinical management.
- Management of avulsed permanent central incisor following trauma to a 9 year old boy reporting within 24 hours.
- Discuss the management of an avulsed tooth
- Discuss the principles of examination in a child with trauma. Describe the management of an avulsed primary tooth.
- Sequelae of replanted avulsed primary and permanent teeth

Recap - Take Home Message

- IADT Guidelines
- Prognosis
- Assessment of Avulsed tooth
- Protocol
- Primary Teeth ? Replant?
- Exam Questions

REFERENCES

- Holan G. Replantation of avulsed primary incisors : a critical review of a controversial treatment. Dent Traumatol 2013; 29: 178-184.
- Martins-Junior PA et al. Replantation of avulsed primary teeth : a systematic review. Int J Ped Dent 2014; 24: 77-83.
- Andreasen JO, Andreasen FM, Andersson L. Textbook and color atlas of Traumatic Injuries to the teeth. 4th edition, Blackwell Munksgaard, Copenhagen, Denmark, 2016, p 530.
- Malmgren B et al. International association of dental traumatology guidelines for the management of traumatic dental injuries: 3. Injuries in the primary dentition. Dent Traumatol 2012; 28: 174-182.
- Anderson L et al. International association of dental traumatology guidelines for the management of traumatic dental injuries: 2. Avulsion of permanent teeth. Dent Traumatol 2012; 28: 88 -96.

CONCLUSION

Examinations are just a gateway to the next step. The present education system has given enormous weightage to this process. Whether we like it or not, it is important that we cross this quickly. Then we can venture into a world without examinations…I suggest each and every student should come out of this process at the earliest and to see the world without it. Good luck for your examinations….definitely a different one than you ever had…with all the impact of "new normal" in place.

Thank You for Your Undivided Attention

- Any questions? Happy to answer.
- muthumurugan@gmail.com